European Journal of Orthodontics 32 (2010) 419–424
doi:10.1093/ejo/cjp119
Advance Access Publication 6 January 2010

© The Author 2010. Published by Oxford University Press on behalf of the European Orthodontic Society.
All rights reserved. For permissions, please email: journals.permissions@oxfordjournals.org

Soft tissue profile changes following maxillary protraction in Class III subjects

Nihat Kilic, Gulhan Catal, Ali Kiki and Hüsamettin Oktay
Department of Orthodontics, Faculty of Dentistry, Atatürk University, Erzurum, Turkey

SUMMARY The dentoskeletal effects of maxillary protraction (MP) therapy have been extensively investigated, while those relating to soft tissue profile changes are limited. Thus, the aim of this study was to determine the degree of soft tissue profile changes following MP therapy. The material consisted of the cephalometric films of 24 female subjects (12.69 ± 1.08 years) with a Class III malocclusion who underwent MP therapy; these were compared with a control group of 15 females (12.13 ± 0.63 years) with a Class I occlusion and matched for chronological age and observation period. Cephalometric films were available for all subjects before (T1) and after (T2) treatment/observation. The initial measurements and treatment/control changes were compared between the groups by means of a Student's *t*-test.

The subjects in the MP group had a concave facial profile when compared with the controls. Comparison of the changes induced by MP therapy showed that the maxilla and surrounding soft tissues showed significant anterior movement ($P < 0.001$), whereas the mandible and surrounding soft tissues showed a backward and downward rotation. The improvement in facial profile predominantly resulted from maxillary soft tissue changes and mandibular hard tissue changes. The concave soft tissue profiles of the Class III subjects were corrected by anterior movement of the maxilla and a concomitant increase in the fullness of the upper lip. The concave skeletal profiles were, however, corrected mainly by backward and downward rotation of the mandible.

Introduction

Class III patients often show an anterior crossbite with a concave soft tissue profile. Class III malocclusion subjects can exhibit a variety of skeletal and dental components. Skeletal manifestations of the malocclusion include (Ngan, 2001): a normally positioned maxilla and prognathic mandible, a retrusive maxilla and normally positioned mandible, or a retrusive maxilla and prognathic mandible. Dental components of the malocclusion may include a protrusive maxillary and/or retrusive mandibular dentition (Guyer *et al.*, 1986).

Protraction of the maxilla with a facemask is a common treatment procedure for Class III malocclusions with maxillary retrusion and mandibular protrusion. The primary aim of this procedure is t o obtain well-balanced faces by enhancing growth of the mid-facial structures (Campbell, 1983; McNamara and Brudon, 1993). The effects of treatment with such orthopaedic appliances have been extensively investigated and reported to be as follows: acceleration of forward growth of the maxilla with a counterclockwise rotation, forward movement of the maxillary dentition, retardation of mandibular growth, and backward movement of the mandible with a clockwise rotation (Irie and Nakamura, 1975; Campbell, 1983; Allen *et al.*, 1993; Deguchi and Kitsugi, 1996; Sung and Baik, 1998; Üçüncü *et al.*, 2000).

The primary goal of treatment of Class III subjects should be to obtain an excellent or acceptable soft tissue profile, unlike in other malocclusion groups, since the main concern of these patients is their soft tissue profiles. Holdaway (1983) stated that 'The soft tissue profile plays an important part in our orthodontic considerations. Usually, as we correct malocclusions, we bring about changes in appearance that are pleasing to all concerned.'

The soft tissue response to orthopaedic treatment of Class III malocclusions, with a chin cup or maxillary protraction (MP) appliances, has been investigated in previous studies (Lin *et al.*, 1985; Ngan *et al.*, 1996a,b; Kiliçoglu and Kirliç, 1998; Abu Alhaija and Richardson, 1999; Arman *et al.*, 2004, 2006; Kircelli and Pektas, 2008). In the most of these studies, the focus was on soft tissue changes induced by combined rapid maxillary expansion (RME) and MP. Arman *et al.* (2004, 2006) and Ngan *et al.* (1996a,b) noted significant improvement in the soft tissue profile as a result of this combined therapy.

Surprisingly, little interest has been given to the soft tissue changes induced only by MP (Kiliçoglu and Kirliç, 1998; Kircelli and Pektas, 2008). Kiliçoglu and Kirliç (1998) evaluated Delaire mask therapy in growing children with a mean age of 8.5 years, and found that soft tissue profile changes were characterized by forward movement of the upper lip and backward repositioning of soft pogonion. In a recent study, Kircelli and Pektas (2008) used skeletal anchorage in conjunction with facemask therapy and found remarkable advancement in the mid face and consequent fullness in the soft tissue profile in patients with a mean age of 11.8 years.

The purpose of this study was to investigate soft tissue profile changes induced by only MP in subjects with maxillary retrusion and mandibular protrusion.

Materials and Methods

The material consisted of the lateral cephalograms of 24 females who underwent MP therapy and of 15 female subjects who served as the controls. The mean ages of the subjects were 12.69 ± 1.08 and 12.13 ± 0.63 years in the treatment and control groups, respectively. Individuals with maxillary retrusion or a combination of maxillary retrusion and mandibular protrusion (dental and skeletal Class III relationship with anterior crossbite and retrusive nasomaxillary area) were included in the treatment group. The selection of the control subjects was based on the presence of normal growth and development, a balanced skeletal profile, Class I occlusion, minimal dental crowding, and the absence of anterior and/or posterior crossbites. None of the subjects had a history of previous orthodontic treatment.

A Petit type face mask was used for MP therapy, and a force of 400–500 g was applied from hooks near the maxillary canines on each side. The direction of force was adjusted to be approximately 20–30 degrees downward from the occlusal plane (Figure 1). The patients were instructed to wear the appliances for at least 14 hours per day until a positive overjet was achieved.

Cephalometric radiographs were obtained before (T1) and after (T2) MP therapy in the study group. The films of the control subjects were obtained from the longitudinal archive of the Department of Orthodontics, University of Atatürk, Erzurum, Turkey. All cephalometric films were taken in the same cephalostat (Siemens Nanodor 2, Siemens AG, Munich, Germany) in habitual, unstrained body posture. The subjects were requested to keep their teeth in centric occlusion during exposure, and special attention was given to ensure that the lips were at rest to overcome possible soft tissue distortion. The observation period of the control subjects corresponded with the treatment time in the study group.

Twelve linear and seven angular parameters were measured on the radiographs to determine the treatment and growth changes in both soft tissue profile and hard tissues. These measurements were adopted from the studies of Nanda *et al.* (1990) and Varlik *et al.* (2008). The landmarks and the measurements used in the present study are shown in Figures 2 and 3, respectively.

Statistical analysis

To determine the errors associated with digitizing and measurements, 15 radiographs were randomly selected, and landmark identification, tracing, and measurement were repeated after a period of 2 weeks by the same author (GÇ).

Figure 1 Petit type face mask.

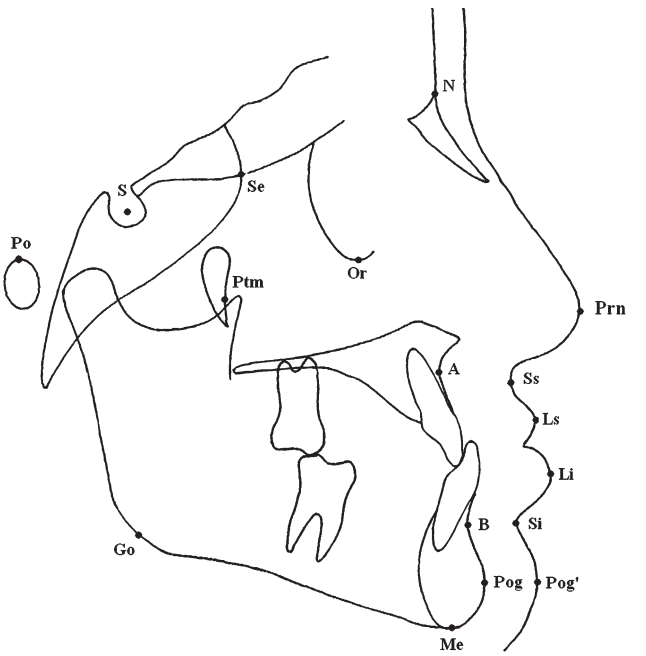

Figure 2 Landmarks used in the study: S, sella; N, nasion; Or, orbitale; Ss, sulcus superior; Ls, labrale superior; Li, labrale inferior; Si, sulcus inferior; Pog', soft tissue pogonion; A, point A; B, point B; Pog, pogonion; Me, menton; Go, gonion; Po, porion; Se, intersection of the greater wing of the sphenoid bone with the floor of anterior cranial fossa; Ptm, the most inferior and posterior point on the anterior outline of pterygomaxillary fissure; Prn, pronasale.

Intraclass correlation coefficients were performed to assess the reliability of the measurements (Houston, 1983). The coefficients of reliability for all measurements were above 0.90.

The measurements of both groups at T1 were compared by means of a Student's *t*-test. The changes between T1 and T2 periods were determined and comparisons between the groups were analysed using a Student's *t*-test. All statistical analyses were performed using the Statistical Package for Social Sciences (Windows 98, version 10.0, SPSS Inc., Chicago, Illinois, USA).

Results

The initial chronological ages and observation periods of the study and control groups are shown in Table 1. There was no statistically significant difference between the groups regarding these parameters.

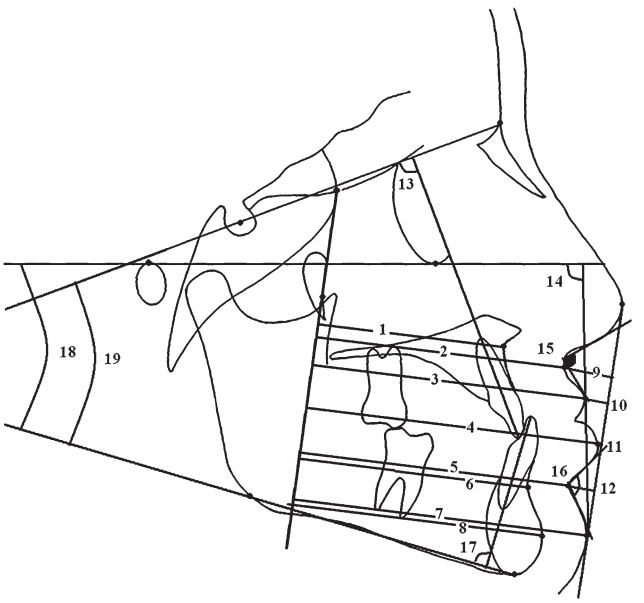

Figure 3 Lines used in the present study: *y*-axis (PMV plane): a line passing through Se and Ptm points. E line: aesthetic line of Ricketts, extending between the nose tip and soft tissue pogonion. Mandibular plane: a plane passing through gonion and menton. Frankfort horizontal plane: horizontal plane passing through porion and orbitale. Linear and angular measurements: (1) A–y, (2) Ss–y, (3) Ls–y, (4) Li–y, (5) Si–y, (6) B–y, (7) Pog'–y, (8) Pog–y, (9) Ss–E, (10) Ls–E, (11) Li–E, (12) Si–E, (13) U1–SN, (14) Z angle, (15) nasolabial angle, (16) labiomental angle, (17) IMPA, (18) FMA (Frankfort-mandibular plane angle), (19) SN–GoMe.

The results of the Student's *t*-test comparing the initial values of the groups are shown in Table 2. The distance from point A to PMV and lower incisor inclination (IMPA) were significantly less, whereas superior sulcus and labial superior to E line measurements were greater in the treated group. Point B and inferior sulcus to PMV measurements and labiomental angle were found to be greater in the MP group.

The changes which occurred during the treatment and observation periods are shown in Table 3. Changes in all measurements, except Li–E distance and nasolabial angle, were significantly different between the groups. The maxilla (A–y), superior sulcus (Ss–y, Ss–E), and upper lip (Ls–y, Ls–E) showed significantly greater anterior movement, but the mandible (B–y, Pog–y, Pog'–y) and lower lip (Li–y, Si–y) showed posterior movement in the MP group. The distance between inferior sulcus to the E line (Si–E) increased in the control group but decreased in the MP group; these changes were statistically significant. The upper incisors proclined, the lower incisors retroclined, and Z and labiomental angles decreased significantly in the MP group. The vertical dimensions of the face also significantly increased in the MP group.

Discussion

The soft tissue facial profile has been considered by patients and orthodontists as an important objective of orthodontic/orthopaedic therapy, especially in patients with a concave facial profile and Class III malocclusion (Kiliçoglu and Kirliç, 1998). Thus, the main aim of the present research was to evaluate the soft tissue profile changes induced by MP therapy relative to a control group in subjects with maxillary retrusion and mandibular protrusion.

Since ethical principles did not allow postponement of treatment in Class III subjects for scientific purposes, the control group was formed of subjects with an acceptable occlusion and a skeletal Class I relationship. Many authors have used Class I untreated samples as control groups (Ishii *et al.*, 1987; Takada *et al.*, 1993; Kapust *et al.*, 1998; Sung and Baik, 1998; Altug and Arslan, 2006). The chronological ages of the control subjects and the control durations were closely matched to those of the subjects in the study group.

The main focus of the present research was to determine treatment outcomes of Class III patients aged 11–16 years.

Table 1 Initial chronological age and observation periods of the groups and their comparison.

Parameters	Study group (n = 24)		Control group (n = 15)		
	Mean	Standard deviation	Mean	Standard deviation	Test
Chronological age (years)	12.69	1.08	12.13	0.63	Not significant
Observation period (months)	12.08	3.68	12.06	0.46	Not significant

Table 2 The means and standard deviation (SD) of the initial cephalometric values of the two groups (Student's *t*-test)

Parameters	Study group (n = 24)		Control group (n = 15)		P value
	Mean	SD	Mean	SD	
A–y	48.75	2.40	50.37	2.00	0.036*
Ss–y	65.04	3.34	66.07	2.46	0.311
Ls–y	69.13	3.70	70.07	3.07	0.416
Li–y	72.47	4.98	69.90	3.62	0.092
B–y	57.04	6.21	52.90	3.89	0.027*
Si–y	68.10	5.78	64.13	3.13	0.020*
Pog–y	60.02	7.79	56.17	4.75	0.094
Pog'–y	71.60	7.68	67.57	4.78	0.077
Ss–E	−11.69	1.97	−8.87	1.32	0.000***
Ls–E	−6.79	2.07	−3.53	1.81	0.000***
Li–E	−2.06	2.84	−1.53	2.08	0.537
Si–E	−5.02	2.63	−5.70	1.53	0.370
U1–SN	101.88	4.92	102.57	6.88	0.716
Z angle	82.81	4.56	80.07	5.15	0.090
Nasolabial angle	107.27	8.88	103.93	8.51	0.253
Labiomental angle	139.52	12.02	127.57	13.45	0.006**
IMPA	84.92	6.23	91.07	4.80	0.002**
SN–GoMe	35.83	4.56	34.10	3.84	0.229
FMA	28.54	4.24	27.03	3.95	0.275

*$P < 0.05$; **$P < 0.01$; ***$P < 0.001$.

Table 3 Comparisons of mean changes and standard deviations between the groups (Student's *t*-test).

Parameters	Study group (n = 24)		Control group (n = 15)		P value
	Mean	Standard deviation	Mean	Standard deviation	
A–y	1.48	0.79	0.49	0.27	0.000***
Ss–y	1.81	0.96	0.47	0.40	0.000***
Ls–y	2.13	1.45	0.40	0.34	0.000***
Li–y	−1.16	2.44	0.20	0.37	0.040*
B–y	−2.46	2.23	0.50	0.33	0.000***
Si–y	−2.38	2.31	0.33	0.31	0.000***
Pog–y	−2.06	2.68	0.67	0.31	0.000***
Pog'–y	−2.17	2.30	0.60	0.28	0.000***
Ss–E	1.15	0.90	0.43	1.15	0.037*
Ls–E	2.02	1.26	0.50	1.82	0.004**
Li–E	−0.17	1.55	−0.03	1.52	0.794
Si–E	−0.83	0.99	0.17	0.56	0.001**
U1–SN	3.31	3.86	0.40	0.60	0.006**
Z angle	–4.48	2.54	0.67	1.42	0.000***
Nasolabial angle	–0.15	9.66	–0.13	1.51	0.996
Labiomental angle	–6.38	8.35	0.07	1.05	0.005**
IMPA	−2.98	2.54	0.07	0.18	0.000***
SN–GoMe	2.48	2.29	0.17	0.24	0.000***
FMA	2.81	2.50	0.13	0.30	0.000***

*$P < 0.05$; **$P < 0.01$; ***$P < 0.001$.

There is controversy regarding the timing of facemask therapy. Mermigos *et al.* (1990) and Baccetti *et al.* (1998) noted that greater skeletal changes with MP appliances are possible at younger ages. Clinical experience suggests that stimulation of the circum-maxillary sutures at an early phase of growth can provide favourable treatment results. Kim *et al.* (1999) showed in a meta-analysis that more favourable outcomes occurred in younger (4–10 years) than older (10–15 years) subjects, although the differences were not statistically significant. This was also found by Altug and Arslan (2006), where favourable skeletal changes occurred during the pubertal growth spurt.

On the contrary, some clinical studies have shown that treatment changes in different age groups ranging from 7 to 13 years were not statistically significant regarding skeletal parameters (Mermigos *et al.*, 1990). Kapust *et al.* (1998) divided their patients into three age groups (4–7, 7–10, and 10–14 years) and found minimal statistical difference between the three groups. Yüksel *et al.* (2001) found no significant difference between early (9 years 8 months) and late (12 years 6 months) treatment groups.

The Class III subjects in the present study exhibited a retrusive maxilla and upper lip, a protrusive mandible and lower lip, and compensated incisors, which are the main characteristics of a Class III malocclusion (Table 2). The pre-treatment features of the sample were almost coincident with relevant studies in the literature (Guyer *et al.*, 1986; Battagel, 1993; Kiliçoglu and Kirliç, 1998; Mouakeh, 2001; Ngan, 2001; Arman *et al.*, 2004, 2006).

The results of this study showed that significantly greater anterior movement occurred in the maxilla, upper lip, and superior sulcus (approximately 1.5, 2 and 1.8 mm, respectively) in the MP group than in the control group. There is a consensus that forward movement of the basal maxilla and upper lip inevitably occurs (Baik, 1995; Ngan *et al.*, 1996a,b; Baccetti *et al.*, 1998; Kim *et al.*, 1999; Yoshida *et al.*, 2007). According to the relevant studies, disarticulation of the maxilla with MP therapy, with and without RME, produces significant anterior movement of the mid-face. The findings of the present study are almost in agreement with those of Arman *et al.* (2004, 2006), who investigated the effects of MP with RME in growing children (mean age 11 years 6 months). In a meta-analysis of 14 articles, Kim *et al.* (1999) reported that point A moved between 0.9 and 2.9 mm in the horizontal plane after MP plus RME.

Kircelli and Pektas (2008) evaluated the effects of mid-facial protraction with skeletal anchorage. Those authors reported greater movements in the basal maxilla and upper lip (4.8 and 3.3 mm) than those observed in the current research. Kiliçoglu and Kirliç (1998) evaluated profile changes of subjects treated with the Delaire type facemask and found more prominent anterior movements in both the maxilla and upper lip area than those in this study. Appliance design and the age of the subjects may be reasons for these differences.

Statistical analysis showed that the upper incisors proclined significantly compared with the controls. Üçüncü *et al.* (2000), Arman *et al.* (2004, 2006), and

Altug and Arslan (2006) showed similar changes after MP with RME. Since the appliance was anchored to the upper first premolars and molars, upper incisor proclination after MP therapy was expected. On the contrary, Kircelli and Pektas (2008) and Kiliçoglu and Kirliç (1998) reported insignificant changes in the inclination of the upper incisors. It must be remembered that Kircelli and Pektas (2008) used a skeletal anchorage system on young patients and that earlier therapy produces skeletal rather than dentoalveolar changes.

The results of the present study showed that MP therapy induced a downward and backward movement of the mandible and surrounding soft tissues (lower lip and soft tissue pogonion). These findings are compatible with previous studies (Baik, 1995; Kiliçoglu and Kirliç, 1998; Arman *et al.*, 2004, 2006; Wells *et al.*, 2006). Considering that the centre of resistance of the maxilla is between the root apices of first and second premolars (Hirato, 1984; Tanne *et al.*, 1988), protraction forces at the level of the occlusal plane inevitably produce upward and forward rotation of that the maxilla (Ichikawa, 1984). It has been shown that significant posterior rotation of the palatal plane and extrusion of the posterior teeth occurs after MP (Ngan *et al.*, 1996a,b; Kiliçoglu and Kirliç, 1998; Alcan *et al.*, 2000; Arman *et al.*, 2004, 2006). In addition to this rotation, the force exerted by the chin cup of the appliance has been speculated to induce redirection of the mandible downward and backward during MP (Kim *et al.*, 1999). This backward rotation of the mandible during chin cup therapy is thought to be important in correcting Class III malocclusions (Deguchi *et al.*, 2002).

It was observed that the lower incisors retroclined after MP. It is postulated that this effect occurs as a result of the pressure exerted by the chin cup and soft tissues (Ngan *et al.*, 1996a; Kim *et al.*, 1999; Arman *et al.*, 2004). The significant change in labiomental angle is the result of lower incisor retroclination and adaptation to the changes in the hard tissues.

The Class III malocclusion and concave facial profile of the subjects were mainly corrected by hard and soft tissue improvements in the sagittal direction and, to some extent, by vertical movement of the mandible and dentoalveolar changes. Since soft and hard tissue profile changes in the sagittal direction have a pronounced impact on the correction of the concave soft tissue facial profile of Class III subjects, focussing on soft tissues may result in apparently pleasing faces. The data in the present study clearly show that soft tissue changes in the sagittal direction were mainly the result of improvements in the upper lip (60 per cent anterior movement of upper lip, 40 per cent posterior movement of lower lips); the upper lip moved anteriorly 2.13 mm and the lower lip posteriorly 1.16 mm relative to the PMV reference line. Hard tissue changes in the maxilla and mandible were in reverse order (60 per cent posterior movement of the mandible, 40 per cent anterior movement of the maxilla). This means that the soft tissue effects are mainly in the maxillary region and the hard tissue effects in the mandibular region. According to Ngan *et al.* (1996a), forward movement of the maxilla is accompanied by a corresponding increase (50–79 per cent) in the soft tissues, whereas mandibular repositioning is accompanied by a corresponding reduction (71–81 per cent) of the soft tissues. Soft tissue changes after MP therapy have been noted by Kiliçoglu and Kirliç (1998) and Arman *et al.* (2004, 2006). Kircelli and Pektas (2008) reported that improvement in facial aesthetics using skeletal anchorage in conjunction with facemask therapy mainly resulted from mid-facial and infraorbital changes.

Conclusions

1. Significant changes were observed in the hard and soft tissue profile and incisor inclinations after facemask therapy.
2. The maxilla and surrounding soft tissues showed significant anterior movement, whereas the mandible and surrounding soft tissues rotated backward and downward.
3. Concave soft tissue profiles were corrected by anterior movement of the maxilla and a concomitant increase in the fullness of the upper lip. Concave skeletal profiles, however, were corrected mainly by backward and downward rotation of the mandible.
4. The results of MP without RME were similar to those of a facemask plus RME.

Address for correspondence

Dr Nihat Kiliç
Ortodonti Anabilim Dalı
Diş Hekimliği Fakültesi
Atatürk Üniversitesi
25240 Erzurum
Turkey
E-mail: drnkilic@yahoo.com

References

Abu Alhaija E S, Richardson A 1999 Long-term effect of the chincap on hard and soft tissues. European Journal of Orthodontics 21: 291–298

Alcan T, Keles A, Erverdi N 2000 The effects of a modified protraction headgear on maxilla. American Journal of Orthodontics and Dentofacial Orthopedics 117: 27–38

Allen A R, Connolly H I, Richardson A 1993 Early treatment of Class III incisor relationship using the chincap appliance. European Journal of Orthodontics 15: 371–376

Altug Z, Arslan A D 2006 Skeletal and dental effects of a mini maxillary protraction appliance. Angle Orthodontist 76: 360–368

Arman A, Toygar T U, Abuhijleh E 2004 Profile changes associated with different orthopedic treatment approaches in Class III malocclusions. Angle Orthodontist 74: 733–740

Arman A, Ufuk Toygar T, Abuhijleh E 2006 Evaluation of maxillary protraction and fixed appliance therapy in Class III patients. European Journal of Orthodontics 28: 383–392

Baccetti T, McGill J S, Franchi L, McNamara J A, Tollaro I 1998 Skeletal effects of early treatment of Class III malocclusion with maxillary expansion and face-mask therapy. American Journal of Orthodontics and Dentofacial Orthopedics 113: 333–343

Baik H S 1995 Clinical results of the maxillary protraction in Korean children. American Journal of Orthodontics and Dentofacial Orthopedics 108: 583–592

Battagel J M 1993 The aetiological factors in Class III malocclusion. European Journal of Orthodontics 15: 347–370

Campbell P M 1983 The dilemma of Class III treatment. Early or late?. Angle Orthodontist 53: 175–191

Deguchi T, Kitsugi A 1996 Stability of changes associated with chin cup treatment. Angle Orthodontist 66: 139–146

Deguchi T, Kuroda T, Minoshima Y, Graber T M 2002 Craniofacial features of patients with Class III abnormalities: growth-related changes and effects of short-term and long-term chincup therapy. American Journal of Orthodontics and Dentofacial Orthopedics 121: 84–92

Guyer E C, Ellis E E, McNamara J A, Behrents R G 1986 Components of Class III malocclusion in juveniles and adolescents. Angle Orthodontist 56: 7–30

Hirato R 1984 An experimental study of the center of resistance of nasomaxillary complex: two-dimensional analysis on the coronal plane of the dry skull. Journal of Tokyo Dental College 84: 1225–1262

Holdaway R A 1983 A soft-tissue cephalometric analysis and its use in orthodontic treatment planning. Part I. American Journal of Orthodontics 84: 1–28

Houston W J B 1983 The analysis of errors in orthodontic measurements. American Journal of Orthodontics 83: 382–390

Ichikawa K 1984 The effects of orthopedic forces on the craniofacial complex utilizing maxillary protraction. Journal of Japan Orthodontic Society 43: 326–338

Irie M, Nakamura S 1975 Orthopedic approach to severe skeletal Class III malocclusion. American Journal of Orthodontics 67: 377–392

Ishii H, Morita S, Takeuchi Y, Nakamura S 1987 Treatment effect of combined maxillary protraction and chincap appliance in severe skeletal Class III cases. American Journal of Orthodontics and Dentofacial Orthopedics 92: 304–312

Kapust A J, Sinclair P M, Turley P K 1998 Cephalometric effects of face mask/expansion therapy in Class III children: a comparison of three age groups. American Journal of Orthodontics and Dentofacial Orthopedics 113: 204–212

Kiliçoglu H, Kirliç Y 1998 Profile changes in patients with Class III malocclusions after Delaire mask therapy. American Journal of Orthodontics and Dentofacial Orthopedics 113: 453–462

Kim J H, Viana M A, Graber T M, Omerza F F, BeGole E A 1999 The effectiveness of protraction face mask therapy: a meta-analysis. American Journal of Orthodontics and Dentofacial Orthopedics 115: 675–685

Kircelli B H, Pektas Z O 2008 Midfacial protraction with skeletally anchored face mask therapy: a novel approach and preliminary results. American Journal of Orthodontics and Dentofacial Orthopedics 133: 440–449

Lin J X, Huang J, Zeng X L 1985 A cephalometric evaluation of hard and soft tissue changes during Class III traction. European Journal of Orthodontics 7: 201–204

McNamara J A, Brudon W L 1993 Orthopedic facial mask therapy. Orthodontic and orthopedic treatment in the mixed dentition. Neetham Press, Ann Arbor, pp. 283–295.

Mermigos J, Full C A, Andreasen G 1990 Protraction of the maxillofacial complex. American Journal of Orthodontics and Dentofacial Orthopedics 98: 47–55

Mouakeh M 2001 Cephalometric evaluation of craniofacial pattern of Syrian children with Class III malocclusion. American Journal of Orthodontics and Dentofacial Orthopedics 119: 640–649

Nanda R S, Meng H, Kapila S, Goorhuis J 1990 Growth changes in the soft tissue facial profile. Angle Orthodontist 60: 177–190

Ngan P 2001 Treatment of Class III malocclusion in the primary and mixed dentitions. In: Bishara S E (ed). Textbook of orthodontics W.B. Saunders Company, Philadelphia, pp. 324–374

Ngan P, Hägg U, Yiu C, Merwin D, Wei S H Y 1996a Soft tissue and dentoskeletal profile changes associated with maxillary expansion and protraction headgear treatment. American Journal of Orthodontics and Dentofacial Orthopedics 109: 38–49

Ngan P, Hägg U, Yiu C, Merwin D, Wei S H Y 1996b Treatment response to maxillary expansion and protraction. European Journal of Orthodontics 18: 151–168

Sung S J, Baik H S 1998 Assessment of skeletal and dental changes by maxillary protraction. American Journal of Orthodontics and Dentofacial Orthopedics 114: 492–502

Takada K, Petdachai S, Sakuda M 1993 Changes in dentofacial morphology in skeletal Class III children treated by a modified maxillary protraction headgear and a chin cup: a longitudinal cephalometric appraisal. European Journal of Orthodontics 15: 211–221

Tanne K, Miyasaka J, Yamagata Y, Sachdeva R, Tsutsumi S, Sakuda M 1988 Three dimensional model of the human craniofacial skeleton: method and preliminary results using finite elements analysis. Journal of Biomedical Engineering 10: 246–252

Üçüncü N, Üçem T T, Yüksel S 2000 A comparison of chincap and maxillary protraction appliances in the treatment of skeletal Class III malocclusions. European Journal of Orthodontics 22: 43–51

Varlik S K, Gültan A, Tümer N 2008 Comparison of the effects of Twin Block and activator treatment on the soft tissue profile. European Journal of Orthodontics 30: 128–134

Wells A P, Sarver D M, Proffit W R 2006 Long-term efficacy of reverse pull headgear therapy. Angle Orthodontist 76: 915–922

Yoshida I, Shoji T, Mizoguchi I 2007 Effects of treatment with a combined maxillary protraction and chincap appliance in skeletal Class III patients with different vertical skeletal morphologies. European Journal of Orthodontics 29: 126–133

Yüksel S, Uçem T T, Keykubat A 2001 Early and late facemask therapy. European Journal of Orthodontics 23: 559–568